

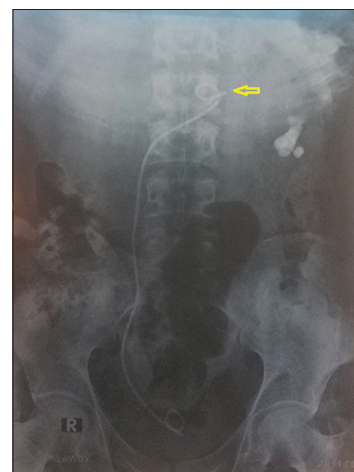## Proximal migration of the ureteral double-J stent into the peritoneal cavity without peritonitis: A Rare Complication

Faisal Ahmed<sup>1</sup>, Abdulfattah Altam<sup>2</sup>, Saif Ghabisha<sup>3</sup>

From <sup>1</sup>Consultant, Department of Urology, <sup>3</sup>Consultant, Department of General Surgery, School of Medicine, Ibb University of Medical Sciences, Ibb, <sup>2</sup>Consultant, Department of General Surgery, School of Medicine, 21 September University, Sana'a, Yemen

Ureteral double J (DJ) stents are associated with complications such as malposition, migration, fragmentation, and “forgotten stent,” and are known to migrate both proximally and distally [1,2]. We presented a 40-year-old man who had complained of decreased urination, nausea, and abdominal pain for a week. The pain was mild and localized in the periumbilical area. There was a history of dysuria and hematuria without fever or abdominal distension. The patient mentioned that another urologist at another center had performed a ureteroscopy and placed a DJ stent for a right distal ureteral stone. On physical examination, localized mild tenderness in the periumbilical area was noted. Laboratory tests revealed a serum creatinine of 6.4 mg/dl, blood urea nitrogen of 125 mg/dL, white blood cells of 12,000/uL, and hemoglobin of 7.6 g/dL. The results of all other blood tests were within the normal range. On plain radiography, the proximal tip of the DJ stent penetrated the peritoneal cavity while the distal end was still in the urinary bladder (Fig. 1). Abdomen ultrasonography (US) revealed increased corticomedullary differentiation and a thin cortex (<5 mm) of both kidneys without any intraabdominal fluid collections. The case was diagnosed with migration of the DJ stent into the abdominal cavity and a treatment plan was established. Urgent hemodialysis, blood transfusion, and broad-spectrum antibiotics were initiated. The DJ stent was then removed cystoscopically without any complications. Postoperatively, the patient was monitored serially with abdominal ultrasound. No fluid accumulation was detected on the abdominal US and the patient reported no symptoms.

Complications associated with ureteral DJ stents can be divided into two groups, namely, short-term and long-term complications. The latter group is related to stent retention over long periods of time and may result in encrustations, stone formation, fractures, blockades of stents, hydronephrosis, and in severe cases, loss of



**Figure 1: The proximal tip of double J stent within the peritoneal cavity (arrow)**

renal function. The former group consists of infection, hematuria, pain, and stent syndrome [3,4].

### Learning Points

Even though the ureteral DJ stent accidentally migrating into the peritoneal cavity is a rare occurrence, the treatment should be administered depending on the patient's general clinical conditions, the time since the injury was discovered, and the nature of the injury.

### CONSENT FOR PUBLICATION


Written informed consent was obtained from the patient for the publication of this case report and all accompanying images. The patient understands that while every effort is made to maintain the confidentiality of his identity, name, and initials, anonymity cannot be guaranteed.

### AUTHORS' CONTRIBUTIONS

All authors contributed to the completion of this work. The final manuscript was read and approved by all authors.

**Correspondence to:** Faisal Ahmed, Department of Urology, School of Medicine, Ibb University of Medical Sciences, Ibb, Yemen. E-mail: fmaaa2006@yahoo.com

© 2023 Creative Commons Attribution-NonCommercial 4.0 International License (CC BY-NC-ND 4.0).

Access this article online	
Received: 29 May 2023 Initial review: 06 June 2023 Accepted: 12 August 2023	Quick Response code 
DOI: 10.32677/yjm.v2i2.4076	

## REFERENCES

1. Ahmed F, Alyhari Q, Ghabisha S, *et al.* Jejunal perforation and upward migration of double J stents during the cystoscopic procedure: A case report and review of literature. *Pan Afr Med J* 2022;42:56.
2. Haghpahan A, Ahmed F, Hosseini SH, *et al.* Peritoneal perforation and peritonitis after antegrade double-J stent insertion: A case report and review of the literature. *Clin Case Rep* 2022;10:e05436.
3. Patil S, Raghuvanshi K, Jain DK, *et al.* Forgotten ureteral double-J stents and related complications: A real-world experience. *Afr J Urol* 2020;26:1-5.
4. Ahmed F, Al-wageeh S, Ghabisha S, *et al.* A case report of forgotten double

J stent with giant calculus formation from the renal pelvis to the bladder. *J Emerg Med Trauma Acute Care* 2021;2021:1-5.

*Funding: None; Conflicts of Interest: None Stated.*

**How to cite this article:** Ahmed F, Altam A, Ghabisha S. Proximal migration of the ureteral double-J stent into the peritoneal cavity without peritonitis: A Rare Complication. *Yemen J Med.* 2023;2(2):116-117.